

Muscle Control and Non-specific Chronic Low Back Pain

Marc Russo, MD*[‡]; Kristiaan Deckers, MD[†]; Sam Eldabe, MD[‡];
 Kyle Kiesel, PhD[§]; Chris Gilligan, MD[¶]; John Vieceli, MSc^{**};
 Peter Crosby, MEngSci^{††}

Objectives: Chronic low back pain (CLBP) is the most prevalent of the painful musculoskeletal conditions. CLBP is a heterogeneous condition with many causes and diagnoses, but there are few established therapies with strong evidence of effectiveness (or cost effectiveness). CLBP for which it is not possible to identify any specific cause is often referred to as non-specific chronic LBP (NSCLBP). One type of NSCLBP is continuing and recurrent primarily nociceptive CLBP due to vertebral joint overload subsequent to functional instability of the lumbar spine. This condition may occur due to disruption of the motor control system to the key stabilizing muscles in the lumbar spine, particularly the lumbar multifidus muscle (MF).

Methods: This review presents the evidence for MF involvement in CLBP, mechanisms of action of disruption of control of the MF, and options for restoring control of the MF as a treatment for NSCLBP.

Results: Imaging assessment of motor control dysfunction of the MF in individual patients is fraught with difficulty. MRI or ultrasound imaging techniques, while reliable, have limited diagnostic or predictive utility. For some patients, restoration of motor control to the MF with specific exercises can be effective, but population results are not persuasive since most patients are unable to voluntarily contract the MF and may be inhibited from doing so due to arthrogenic muscle inhibition.

Conclusions: Targeting MF control with restorative neurostimulation promises a new treatment option.

Keywords: Arthrogenic muscle inhibition, chronic low back pain, lumbar multifidus, motor control exercises, restorative neurostimulation

Conflict of Interest: Dr. Russo consults for Medtronic, Abbott, Boston Scientific, Nevro, Stimwave, Saluda, and Mainstay Medical. He also has equity holdings in Freedom Neuro, Lungpacer, and SPR Therapeutics. Dr. Russo has a patent licensed to Nevro. Dr. Deckers consults for Mainstay Medical, and is a shareholder and advisor for TrainM NV (Antwerp, Belgium). Prof. Eldabe consults for Mainstay Medical, Medtronic, St Jude Medical, Boston Scientific, Saluda Medical and Axonics. Prof. Kiesel consults for Mainstay Medical and an equity partner in Functional Movement Systems. Dr. Gilligan consults for Mainstay Medical, Medtronic, Whale Imaging, Axial Healthcare, and Nuvector. Mr. Vieceli consults for Mainstay Medical. Mr. Crosby is an employee and shareholder of Mainstay Medical.

INTRODUCTION

Low back pain (LBP) is usually defined as pain and discomfort, localized below the costal margin and above the inferior gluteal fold, with or without referred leg pain (1,2). The NIH Task Force on Research Standards for Chronic LBP (CLBP) recommended (3) that CLBP be defined as a back pain problem that has persisted for at least three months and has resulted in pain on at least half the days in the past 6 months.

The World Health Organization reports that "Low back pain is the most prevalent of musculoskeletal conditions; it affects nearly everyone at some point in time and about 4–33% of the population at any given point" (2). LBP is now the leading cause of disability globally (4,5) There are many publications on the epidemiology (6) of back pain including its prevalence (7–9), natural history, demographics, and country by country variability.

There are many causes for CLBP, and the differential diagnosis can be challenging (10). Specific causes for LBP are uncommon (<15% of all back pain) (1,11). Specific LBP is defined as symptoms caused by a specific pathophysiologic mechanism, such as herniated nuclei pulposus, infection, osteoporosis, rheumatoid arthritis, fracture, or

Address correspondence to: Marc Russo, MD, Hunter Pain Clinic, 91 Chatham Street, Broadmeadow, NSW 2292, Australia. Email: algoguy@gmail.com

* Hunter Pain Clinic, Broadmeadow, NSW, Australia;

† GZA Hospitals, Wilrijk, Belgium;

‡ The James Cook University Hospital, Middlesbrough, UK;

§ University of Evansville, Evansville, IN, USA;

¶ Brigham and Women's Hospital, Boston, MA, USA;

** Physioscope Pain Medicine of SA, South Australia, Australia; and

†† Mainstay Medical International plc, Dublin, Ireland

For more information on author guidelines, an explanation of our peer review process, and conflict of interest informed consent policies, please go to <http://www.wiley.com/WileyCDA/Section/id-301854.html>

Source(s) of financial support: The review was sponsored by Mainstay Medical International plc.

This is an open access article under the terms of the Creative Commons Attribution-NonCommercial-NoDerivs License, which permits use and distribution in any medium, provided the original work is properly cited, the use is non-commercial and no modifications or adaptations are made.

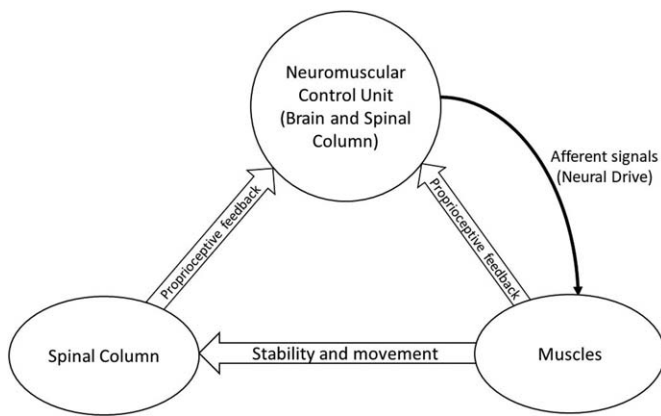


Figure 1. Model of spine stability.

tumor (12). The remaining patients, who comprise the majority of patients, are commonly referred to as having “non-specific LBP” (NSLBP) or “axial LBP” (ALBP) or “Mechanical LBP.” These terms can have different meanings to different audiences of clinicians and researchers.

LBP presents on a spectrum between primarily neuropathic pain and primarily nociceptive pain, and guidelines (13) and tools exist for clinical classification (14,15). Inconsistent nomenclature complicates a review, for example merely describing CLBP as “axial” does not help with understanding if the described therapy is for predominantly neuropathic or predominantly nociceptive CLBP, as axial LBP is a syndrome that may have both nociceptive and neuropathic components (16). This review will concentrate on primarily nociceptive CLBP, which is poorly served with most of today’s treatments. In many cases, the therapy of last resort is opioids.

Clinical Instability and CLBP

Panjabi (17,18) described the stabilizing system of the spine as divided into three subsystems: 1) the spinal column; 2) the spinal muscles; and 3) the neural control unit; spine stability depends on the complex interplay of these three systems. This is illustrated conceptually in Figure 1 (after Panjabi). Disturbances in one or more of these three stabilizing mechanisms leads to spinal segments moving outside of their normal range of motion (the so-called neutral zone), causing tissue injury and initiating LBP. If, for instance, the muscle control system exerts suboptimal stabilizing forces on the spinal column, overload of the joints and soft tissues surrounding the joints is more likely to occur, leading to primarily nociceptive pain. This lesser muscular control could be caused by decreased neural drive from or feedback to the neurologic structures controlling the muscles and the joints (19).

When looking into muscular stabilization of the lumbar spine, the role of the lumbar multifidus (MF) becomes immediately apparent. The anatomic architecture of the MF is shown in Figure 2 (reproduced from Rosatelli (20) with permission). The deep fascicles of the multifidus generally span a single segment, and are “strategically positioned to provide proprioceptive feedback from the lumbar spine.” In contrast, the intermediate fascicles may have a role in controlling intersegmental movement, whereas the superficial fascicles are capable of providing significant torque in a cranio-caudal direction.

The MF is the strongest stabilizer of the lumbar spine (21), and the combined actions of the bilateral multifidi account for more than two thirds of the stiffness of the spine when in the neutral zone (22). Changes in MF are strongly evident in people with cLBP

(23), and many patients with LBP exhibit atrophy of the MF within days of new back pain (24,25). This atrophy can be seen easily and reliably (26) on MRI. Atrophy may be seen unilaterally or bilaterally, and bilateral atrophy is frequently seen in patients who complain of unilateral pain (25,27). MF changes are apparent in chronic LBP (28,29), in proportion to the duration of symptoms (30), and are not due to a change in muscle fiber type (31). The radiology literature (32) reports that fat infiltration of the MF is apparent in chronic LBP (33,34), and there is evidence that the non-contractile tissue seen on MRI is, indeed, fat (35). Fat infiltration and tissue remodeling may be independent of atrophy (36). Examples of fat infiltration in the MF are shown in Figure 3, with a three level classification system (37). A systematic review (38) provided evidence for the presence of macroscopic changes in lumbar muscle structures of CLBP: “especially a loss of muscle size is seen in the lower lumbar levels, but not in the more cranial lumbar levels.”

Acute LBP usually resolves within weeks in most patients (39), although a meta-analysis with a more stringent definition of acute NSLBP suggests that the majority of patients still experience pain one year from the onset of symptoms (40). MF atrophy, on the other hand, typically persists after resolution of pain (41) in patients with CLBP. This persistent defect in the key local stabilizer muscle could explain why many patients with back pain suffer from recurrences or a waxing and waning course after the initial episode (42).

The mechanism leading to MF atrophy in LBP is probably closely related to arthrogenic muscle inhibition (43). This phenomenon can be readily observed in the quadriceps muscle after traumatic and experimental knee injury (44), and is also encountered in the calf muscles after ankle injury (45). It refers to a mechanism by which pain in a skeletal joint leads to reduced neural drive to the muscle(s) that move or stabilize that joint.

Arthrogenic inhibition is thought to be caused by a change in the discharge of articular sensory receptors due to factors such as swelling, inflammation, joint laxity, and damage to joint afferents. Spinal reflex pathways likely contribute to arthrogenic inhibition, as can be measured by changes in reflex activity in experimentally induced cases (44) and evidence suggests that supra-spinal pathways may also play an important role (44,46,47). Interestingly, arthrogenic inhibition in peripheral joint pathology may involve both type I and type II muscle fibers selectively or both together (48).

Arthrogenic muscle inhibition can occur in the spine consequent to an episode of LBP. Electromyogram (EMG) evidence of reduced neural drive to the MF in back pain patients includes diminished EMG activity (49,50), and alterations in the timing of the recruitment of the short (deep) fascicles of the MF in response to perturbations (29). Pain alters the magnitude of activation of deep MF during certain types of activity (51). Ultrasound imaging evidence of reduced neural drive in back pain patients includes reduced muscle thickness changes with contraction (52–55), reduced ability to cause a muscle thickness change on command (56), and altered contraction patterns with changes in posture (57).

There is evidence from humans and animal models, including ovine (58), porcine (59,60), and feline (61) that induced local injury compromises neural drive to the MF, seen as changes in electrical activity on MF electromyography. Experimentally induced intervertebral disc degeneration in the cat induces pathophysiologic changes to the MF (62). In a rabbit model, the MF becomes stiffer, both in individual fibers and in fiber bundles, in response to experimentally induced intervertebral disc degeneration, and a stiffer muscle can alter the biomechanical properties of the spine stabilizing system (62).

Injury to the spine structures (e.g., joints, ligaments, disc) can disrupt one or more of the spine stability sub-systems (19,63–65).

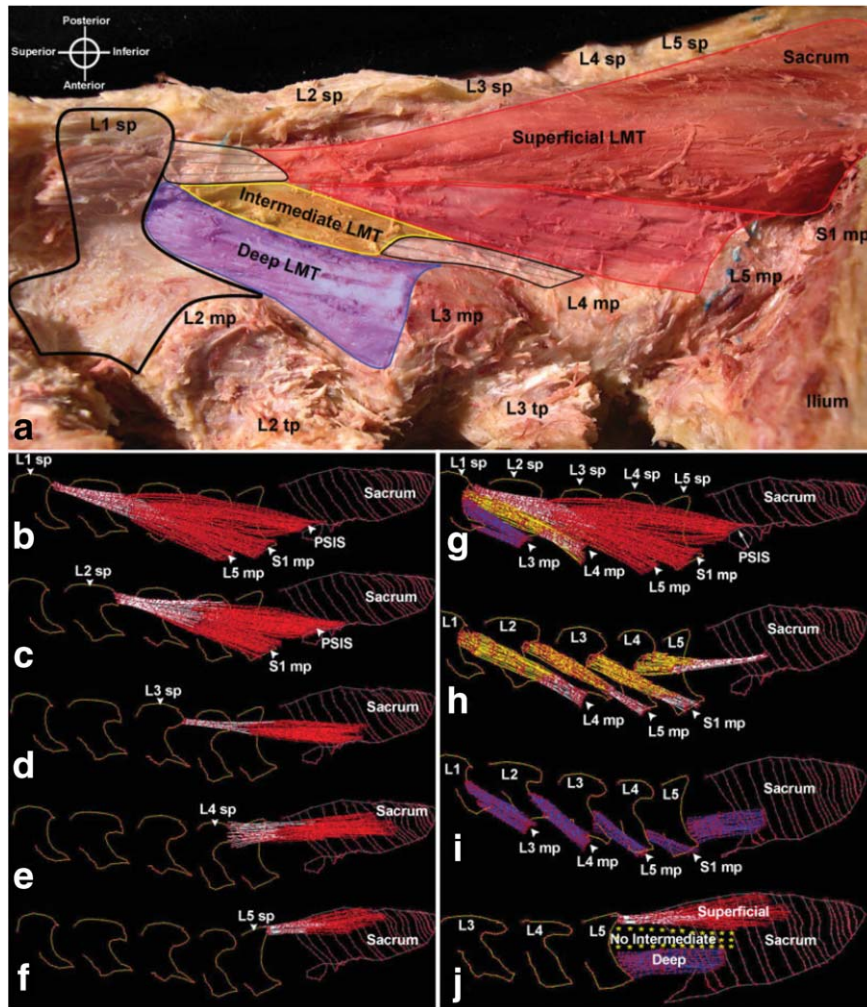


Figure 2. Dissection, digitization, and three-dimensional modeling of lumbar multifidus, lateral views. a. Dissection of superficial (red), intermediate (yellow), and deep (purple) regions. b–f. Segments of the superficial region attaching to L1–L5 spinous processes. g. Three dimensional reconstruction of the digital specimen shown in a. h. Segments of the intermediate region attaching to the L1–L4 spinous processes. Note that there is no intermediate fascicle of the MF attaching to the spinous process at L5. i. Segments of the deep region attaching to the L1–L5 laminae. j. Regions of the LMT attaching to the L5 spinous process. LMT, lumbar multifidus; sp, spinous process; mp, mammillary process; tp, transverse process; PSIS, posterior superior iliac spine; L, lumbar. Reproduced from Rosatelli (20) with permission.

Induced pain studies in humans confirm that local pain of the spinal column leads to reduction of neural drive to the adjacent MF, apparent on functional MRI (66) and ultrasound (67,68). EMG studies of populations of patients with acute or chronic LBP show altered recruitment of the MF (69,70) due to pain, pain avoidance, and deconditioning. Pain has been experimentally shown to reduce neural drive not only to the MF, but also the lumbar erector spinae muscles in both healthy volunteers and back pain patients (71).

Figure 4 shows a representation of compromised spine stability as a result of arthrogenic inhibition. Nociceptive signals (pain) from the spine inhibit the neuromuscular control system (in the brain and spinal cord) which results in reduced neural drive to the muscles which compromises stability and movement. Disrupted neural drive also alters the proprioceptive feedback from the muscles themselves.

Cortical changes in the brain are associated with chronic LBP (72). Impaired motor control of the MF in patients with CLBP is associated with changes in cortical representation of the multifidus and subsequent ability to exert voluntary control (73) and there is evidence of reorganization of trunk muscle representation at the motor cortex in individuals with recurrent LBP. This reorganization is associated with deficits in postural control (74). Individual fascicles of MF are

activated by different regions in the motor cortex (75), and motor control training for back pain patients can reverse the cortical reorganization (76). Evidence of cortical remodeling may be assessed with research techniques of brain mapping using transcranial magnetic stimulation (TMS) and surface EMG recorded at the L3 level, and magnitude of cortical remodeling is associated with severity and location of LBP (77). There is evidence that motor training can reverse pathologic reorganization of neuronal networks of the motor cortex in people with recurrent pain, at least for motor training that focuses on the transverse abdominus (76). Reduction in back pain as a result of facet joint injections or spine surgery has also been shown to be associated with restoration of normal brain anatomy and function (78).

In summary

- The spine stabilization system consists of the spine, the muscles, and the neural control system.
- Arthrogenic muscle inhibition can disrupt control to the key segmental stabilizing muscle of the spine—the lumbar multifidus.
- Disrupted muscle control can lead to compromised clinical stability of the spine, allowing joint overload and consequent persistent and recurrent pain.

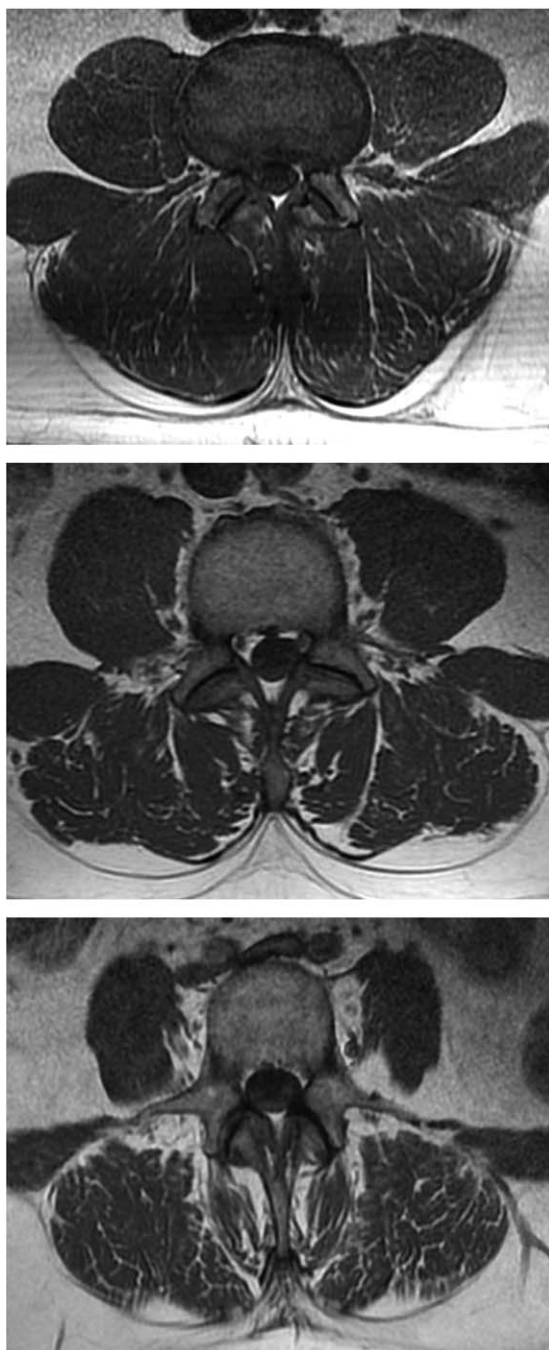


Figure 3. Examples of T1 weighted MRI images of lumbar spine at L3 showing mild (<10%), moderate (10–50%) and severe (>50%) fat infiltration of the lumbar multifidus muscle (images from subjects enrolled in the ReActiv8-B Clinical Trial with permission).

- Back pain due to disrupted muscle control is associated with neuroplastic changes in the motor cortex, which can be reversed with elimination of back pain.

DIAGNOSTIC TESTS FOR MOTOR CONTROL DYSFUNCTION

Since disruption of the MF is clearly associated with CLBP in many cases, it is logical to examine diagnostic tools that can identify patients with this particular pathology.

Imaging Assessment of Motor Control Dysfunction

Changes to the MF apparent with MRI imaging are strongly associated with back pain, but the diagnostic value in individual patients of such changes is limited, since back pain of any cause can lead to changes of the MF cross sectional area and amount of fat infiltration (79). Prolonged bed rest in the absence of back pain can also lead to atrophy of the MF seen on imaging (80) and the atrophy can be reversed with appropriate exercises (81). There appears to be no relationship between MF function and amount of fat infiltration (82). There is some evidence (83) that the severity of fat infiltration correlates with decreased range of motion in flexion, and that the amount of fat infiltration may be a predictor for continued CLBP (84), but the diagnostic utility of these observations is unclear.

Ultrasound imaging has been used to document reduced MF muscle mass, a consequence of reduced neural drive, which in back pain patients includes diminished thickness change with activation (52,53) and reduced ability to cause a muscle thickness change on command (56). Although the measurement techniques have been validated and are reliable, the diagnostic utility is unclear, and ultrasound measured MF activation does not appear to be predictive of which CLBP patients will benefit from stabilization exercises (85). A review (86) states there is “a convincing body of evidence [that] suggests that US imaging is a reliable and valid tool for differentiating LBP patients from normal subjects and monitoring rehabilitation outcome measures.” A later systematic review (87) found “conflicting evidence for a relation between baseline percent thickness change of lumbar multifidus during contraction and the clinical outcomes of patients after various conservative treatments.”

EMG Assessment of Motor Control Dysfunction

EMG evidence has been used to show changes in MF recruitment in populations of patients with CLBP, but has not been shown to be useful as a tool for diagnosis or monitoring therapy in individual patients. Surface EMG cannot be used to accurately record from the MF (88) so fine wire or needle electrodes are more commonly used, but there is no easy way to isolate the EMG signals from the deeper multifidus layers from the surrounding muscles. Even with needle or wire EMG, some far field potentials originating in co-contracting muscles are seen, making it difficult to correctly identify the onset of muscle activity in the multifidus. European Guidelines on NSLBP (1) state the EMG procedures “have no clear relevance to clinical diagnostics although they may still be useful in experimental studies and/or in the rehabilitation environment for examining mechanisms of back muscle function/dysfunction.”

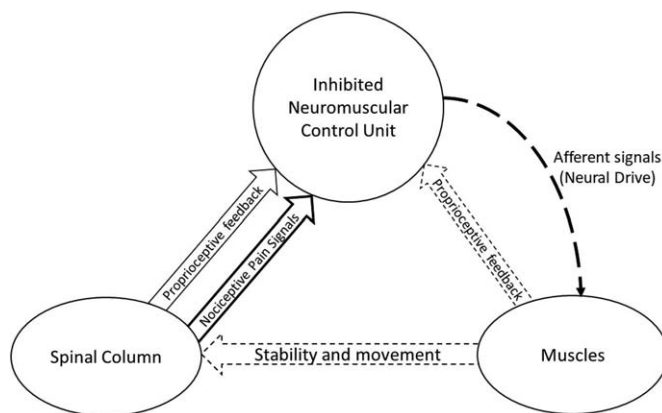


Figure 4. Compromised spine stability.

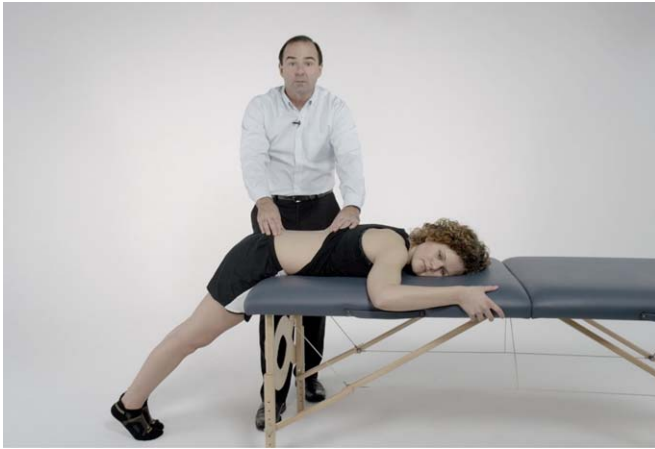

Figure 5. Positioning for starting the Prone Instability Test. We obtained consent for inclusion of the photo from the patient.

Physical Diagnostic Tests for Motor Control Dysfunction

Several tests have been investigated to diagnose patients with CLBP due to motor control impairment including the standing back extension test (89), the prone instability test (PIT) (90), and the multifidus lift test (MLT) (91). The standing back extension test has reliability reported as a Kappa of 0.87, but, the test was validated against the function of deep abdominal muscles only to determine if motor control deficit of the spine were present.

The PIT has adequate interrater reliability (92) (reported as $K = 0.87$) (93) and good face validity. A positive PIT was one of the four variables shown to be predictive of success with a stabilization exercise program for patients with sub-acute LBP (a sample of 40 subjects with an average duration of 75 days) that included exercises designed to reactivate the LM (94). In another study (95), subjects with LBP (a sample of 105 with an average duration of 65 days) who had a positive PIT in conjunction with aberrant movement patterns were shown to have reduced disability and pain following a course of motor control re-training exercises when compared to those subjects who did not have these clinically findings.

The PIT is performed with the patient prone in a relaxed and neutral spine posture (Fig. 5). The tester applies posterior to anterior glides (pressure) over each lumbar segment. If one or more glides produces pain, the glides are repeated when the subject's posterior spinal muscles are activated (extending the hips by lifting the feet off the floor, Fig. 6). If the pain is significantly diminished when the glides are performed during muscle activation, the test is considered positive and suggestive of the presence of a motor control deficit, including MF dysfunction.

Hebert et al. reported the reliability of the MLT, a palpation technique designed to test for MF function. This study used the MLT procedure and compared the results of palpation for the determination of diminished compared to normal multifidus contraction to the measurement of MF muscle thickness change via sonography in 32 subjects with LBP (91). "During the arm lift, the examiner made a qualitative judgment as to whether the participant demonstrated a normal or abnormal lumbar multifidus contraction. This judgment was based on the degree of contraction as determined by muscle palpation. We operationally defined a normal contraction as one in which a robust and obvious muscle contraction could be palpated during the arm lift. We operationally defined an abnormal contraction as occurring when there was little or no palpable contraction of the muscle during the arm lift."

Inter-tester reliability of the MLT at the L4–L5 was reported to be $K = 0.75$ with 86% agreement and at the L5–S1 level demonstrated a $K = 0.81$ with 91% agreement. To establish validity of the test, they assessed the correlation between outcome of the MLT and the ultrasound measure of thickness change. The correlation coefficients demonstrated a consistent relationship (0.59–0.73, $p < 0.01$) between the MLT findings and the ultrasound measures of lumbar multifidus function at L4–L5 and at L5–S1. They reported one examiner that was significant and one was not with a p value = 0.056.

While the PIT has not been specifically validated for LM function, there are data suggesting a relationship between a positive PIT and MF dysfunction. MF reduced thickness change, measured with ultrasound, has been shown to be associated with those who do respond well to a stabilization exercise program (94). Additionally, subjects that were more likely to respond well to the stabilization exercise program had reduced LM thickness change during the MLT. Finally, Herbert et al. demonstrated that subjects who had a positive PIT also had reduced LM thickness change (8.5%) when compared with subjects who had a negative PIT (14.9%). These findings collectively suggest that subjects who test positive on the PIT, may have associated MF dysfunction.

In summary:

- Imaging (x-ray, MRI, ultrasound) diagnostic tests for CLBP due to motor control dysfunction have limited value in individual patients.
- EMG has little value as a diagnostic tool for individual patients with CLBP.
- Physical movement tests (in particular the prone instability test) may be useful to identify patients with CLBP who will benefit for therapies to address motor control dysfunction.

THERAPIES FOR PATIENTS WITH CLBP DUE TO MF DISRUPTION

Exercise Intervention for Restoration of Muscle Control to the MF

The "core stabilizing muscles" of the trunk consists of the erector spinae (ES), transverse abdominus (TrA), and MF, which is the only

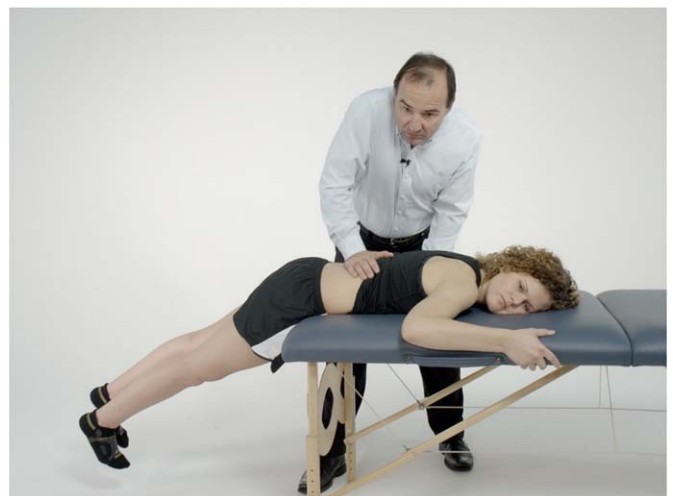

Figure 6. Activation condition for the PIT (note feet are lifted slightly off the floor). We obtained consent for inclusion of the photo from the patient.

muscle in this group that provides segmental stability. Many exercise programs for LBP have focused on “core stabilization exercises” which include the MF. The concept of core stability has both its proponents (96) and its critics (85,97) with strongly held views on both sides and much controversy (98).

There have been many studies on core stabilization exercises to improve back pain associated with spine instability (99–101). Several terms are used with approximately the same meaning including “motor control exercises” (MCE), “spine stabilization exercises,” “lumbar stabilization exercises” and “core strengthening.” There have also been many reviews and meta-analyses of the value of core stabilization exercises (102–108), and the conclusions range between great value and no additional value over normal exercises. Unfortunately, there are no “standards” for core stabilization exercises, so comparison of clinical studies is challenging at best. Furthermore, most studies make no attempt to use diagnostic tests to identify in advance those patients likely to benefit from restoration of MCE, hence any true effect is buried in the noise.

There are few published studies of exercise programs that focus on *just* the multifidus. Interestingly, “generalized” core stabilization exercises have quite mixed results, whereas exercises that target the MF alone or in combination with another muscle generally have more positive clinical results (109,110).

Specific MCE targeting the atrophied MF in some cLBP patients can override the normally involuntary motor control system, restore neural drive to the MF, and lead to recovery from back pain. Ultrasound image guided biofeedback (86) of the MF can help the patient learn to voluntarily contract a muscle not normally subject to voluntary control (111).

This therapy can result in improvements in pain and function in people with CLBP (112–115) including athletes (116,117), and chronic back pain related to spondylosis and spondylolisthesis (118). In addition to reducing symptoms in chronic pain, targeted motor control training can reduce long-term recurrence of back pain in patients with MF atrophy, and reduce the severity of recurrences that do occur (42). The presence of reduced MF activation is a strong predictor (and may be the only useful predictor) of the success of specific targeted training exercises (94).

Unfortunately, targeted MF exercises are difficult to perform and teach, and many patients are simply unable to voluntarily contract a muscle group not normally amenable to voluntary control. In addition, back pain induced arthrogenic muscle inhibition of the spine stabilizing muscles may prohibit any voluntary contraction of the MF.

Neuromuscular Electrical Stimulation (NMES) to Restore Motor Control

In a similar situation, many patients find it difficult or impossible to perform quadriceps strengthening exercises following knee surgery as a result of persistent arthrogenic muscle inhibition. Transcutaneous neuromuscular electrical stimulation (NMES) to cause episodic contraction of the quadriceps alone has been used to restore motor control to allow voluntary contractions and hence facilitate rehabilitation (119,120) following total knee arthroplasty (121) or other surgical procedures (122,123). This treatment has been analyzed in a systematic review (124). Painful knee osteoarthritis can be treated without surgery but may also lead to pain mediated inhibition of neural drive to the quadriceps, which can be treated with NMES (125). It is clear that NMES can restore motor control in some circumstances, and in fact can do so prior to improvements in strength of the quadriceps (126,127). NMES has also been used to restore motor control for swallowing (128).

NMES of the spine stabilizing muscles has not been well researched.¹ Transcutaneous NMES cannot selectively activate deep muscles without also activating the overlying muscles. For example, NMES over the lumbar spine can cause contractions of the superficial fascicles of the MF, but also causes contractions of the transverse abdominus and obliquus internus (129). Transcutaneous NMES over the multifidus has been shown to have no effect (130).

In summary

- A program of biofeedback guided motor control exercise of the MF can restore disrupted motor control to the MF.
- Motor control exercises of the MF may be impossible in the context of arthrogenic inhibition of the MF due to CLBP.
- In the situation of disrupted motor control of the quadriceps from arthrogenic inhibition due to knee pain, transcutaneous neuromuscular electrical stimulation has been shown to restore motor control of the quadriceps.
- Transcutaneous NMES is not suitable for the MF, because the muscle is deep, diffuse, and has extensive overlying muscles.

Restorative Neurostimulation for CLBP

In the same way that electrical stimulation to cause episodic quadriceps contraction can restore neuromuscular control following knee surgery, it was hypothesized that targeted electrical stimulation to cause episodic contraction of the MF alone could lead to restoration of neuromuscular control of the MF, leading to improved functional stability of the lumbar spine and resolution of CLBP. Whereas transcutaneous stimulation to elicit selective MF contractions is not feasible, stimulation of electrodes placed adjacent to the nerve supply to the MF can cause MF only contractions. Direct stimulation of motor nerves to elicit muscle contraction requires two orders of magnitude lower energy than direct stimulation of the muscle mass. Furthermore, direct electrical stimulation of the motor nerves supplying the MF will lead to contraction of the whole muscle innervated by the motor nerve, and not just the region of muscle in the vicinity of the electrodes used for direct muscle stimulation.

A feasibility study to explore this concept using “off the shelf” neurostimulation hardware showed encouraging results (131). Based on the results of this study, a custom implantable neurostimulator was developed and subjected to a single arm clinical trial, which subsequently led to CE Mark approval of the device (see <https://clinicaltrials.gov/ct2/show/NCT01985230>). Results of this trial are presented in this issue of *Neuromodulation* (132).

An international, multi-center, prospective randomized trial with sham control and triple blinding is under way to gather data for a potential submission to the FDA for a Pre-Market Approval (see <https://clinicaltrials.gov/show/NCT02577354>).

CONCLUSION

A significant number of people with primarily nociceptive CLBP have impaired neuromuscular control of the key stabilizing muscles of the lumbar spine as the root cause of their pain, especially impaired control of the lumbar multifidus. These people are generally not candidates for surgery, and are poorly served by existing

¹Note that NMES differs from Transcutaneous Electrical Stimulation (TENS) used as a pain therapy. There are different electrical parameters of stimulation, different proposed mechanisms of action and different modes of use. There is no evidence that TENS is effective for treatment of CLBP (133).

therapies. Exercise therapy targeting restoration of neuromuscular control of the MF has been shown to be effective in some cases, but most people find it difficult or impossible to voluntarily contract the MF. The application of exercise therapy to the MF is limited by the fact that the MF is not normally amenable to voluntary control and may also be subject to arthrogenic muscle inhibition.

Electrical stimulation to restore neuromuscular control of the quadriceps following knee injury or knee surgery has been shown to be effective. The same approach has not been systematically applied to the lumbar spine. Restorative neurostimulation of the MF to mimic the effects of targeted exercise therapy of the MF has been explored in two single-arm clinical trials with encouraging results, and a prospective sham-controlled RCT is under way.

Restorative neurostimulation to cause contraction of the lumbar multifidus holds promise as a new and different approach to treating primarily nociceptive mechanical chronic LBP.

Authorship Statements

Dr. Russo provided overall guidance for the development of the manuscript. Dr. Deckers, Dr. Kiesel, and Mr. Vieceli provided specialized input to the sections on arthrogenic inhibition, and diagnostic tests for mechanical low back pain. Dr. Gilligan contributed to the manuscript in general, and specifically the sections on therapies for CLBP. Mr. Crosby maintained the database of publications, and developed the first draft of the manuscript, and was instrumental in coordinating reviews among all authors. All authors approved the final version of the manuscript.

How to Cite this Article:

Russo M., Deckers K., Eldabe S., Kiesel K., Gilligan C., Vieceli J., Crosby P. 2017. Muscle Control and Non-specific Chronic Low Back Pain. *Neuromodulation* 2017; E-pub ahead of print. DOI:10.1111/ner.12738

REFERENCES

- Airaksinen O, Brox JI, Cedraschi C et al. European guidelines for the management of chronic nonspecific low back pain. *Eur Spine J* 2006;15(Suppl 2):S192–S300.
- Woolf AD, Pfleger B. Burden of major musculoskeletal conditions. *Bull World Health Organ* 2003;81:646–656.
- Deyo R, Dworkin SF, Amtmann D et al. Report of the NIH Task Force on research standards for chronic low back pain. *Spine J* 2014;14:1375–1391.
- Global Burden of Disease Study 2013 Collaborators. Global, regional, and national incidence, prevalence, and years lived with disability for 301 acute and chronic diseases and injuries in 188 countries, 1990–2013: a systematic analysis for the Global Burden of Disease Study 2013. *Lancet* 2015;6736:1990–2013.
- Buchbinder R, Blyth FM, March LM et al. Placing the global burden of low back pain in context. *Best Pract Res Clin Rheumatol* 2013;27:575–589.
- Kent PM, Keating JL. The epidemiology of low back pain in primary care. *Chiropr Osteopat* 2005;13:13.
- Strine TW, Hootman JM. US national prevalence and correlates of low back and neck pain among adults. *Arthritis Rheum* 2007;57:656–665.
- Deyo RA, Mirza SK, Martin BI. Back pain prevalence and visit rates: estimates from U.S. national surveys, 2002. *Spine (Phila Pa 1976)* 2006;31:2724–2727.
- Freburger JK, Holmes GM, Agans RP et al. The rising prevalence of chronic low back pain. *Arch Intern Med* 2009;169:251–258.
- Amirdelfan K, McRoberts P, Deer TR. The differential diagnosis of low back pain: a primer on the evolving paradigm. *Neuromodulation Technol Neural Interface* 2014; 17:11–17.
- Deyo RA, Weinstein JN. Low back pain. *N Engl J Med* 2001;344:363–370.
- Koes BW, van Tulder MW, Thomas S. Diagnosis and treatment of low back pain. *Br Med J* 2006;332:1430–1434.
- Nijls J. Low back pain: Guidelines for the clinical classification of predominant neuropathic, nociceptive, or central sensitization pain. *Pain Physician* 2015;18: E333–E346.
- Freyenhagen R, Baron R, Gockel U, Tölle TR. painDETECT: a new screening questionnaire to identify neuropathic components in patients with back pain. *Curr Med Res Opin* 2006;22:1911–1920.
- Nijls J, Torres-Cueco R, van Wilgen CP et al. Applying modern pain neuroscience in clinical practice: criteria for the classification of central sensitization pain. *Pain Physician* 2014;17:447–457.
- Förster M, Mahn F, Gockel U et al. Axial low back pain: one painful area – many perceptions and mechanisms. *PLoS One* 2013;8:e68273.
- Panjabi MM. The stabilizing system of the spine. Part I. Function, dysfunction, adaptation, and enhancement. *J Spinal Disord* 1992;5:383–389. discussion: 397.
- Panjabi MM. Panjabi – 1992 – the stabilizing system of the spine. Part II. Neutral zone and instability hypothesis.pdf. *J Spinal Disord* 1992;5:390–396. discussion: 397.
- Panjabi MM. Clinical spinal instability and low back pain. *J Electromyogr Kinesiol* 2003;13:371–379.
- Rosatelli AL, Ravichandiran K, Agur AM. Three-dimensional study of the musculotendinous architecture of lumbar multifidus and its functional implications. *Clin Anat* 2008;21:539–546.
- Kim CW, Gottschalk LJ, Eng C, Ward SR, Lieber RL. The multifidus muscle is the strongest stabilizer of the lumbar spine. *Spine J* 2007;7:765.
- Wilke H-J, Wolf S, Claes LE, Arand M, Wiesend A. Stability increase of the lumbar spine with different muscle groups. A biomechanical in vitro study. *Spine (Phila Pa 1976)* 1995;20:192–198.
- Freeman MD, Woodham MA, Woodham AW. The role of the lumbar multifidus in chronic low back pain: a review. *PM R* 2010;2:142–146.
- Hides JA, Stokes M, Saide M, Jull GA, Cooper DH. Evidence of lumbar multifidus muscle wasting ipsilaterally to symptoms in patients with acute/subacute low back pain. *Spine (Phila Pa 1976)* 1994;19:165–172.
- Fortin M, Macedo LG. Multifidus and paraspinal muscle group cross-sectional areas of patients with low back pain and control patients: a systematic review with a focus on blinding. *Phys Ther* 2013;93:873–888.
- Hu Z-J, He J, Zhao F-D et al. An assessment of the intra- and inter-reliability of the lumbar paraspinal muscle parameters using CT scan and magnetic resonance imaging. *Spine (Phila Pa 1976)* 2011;36:E868–E874.
- Beneck GJ, Kulig K. Multifidus atrophy is localized and bilateral in active persons with chronic unilateral low back pain. *Arch Phys Med Rehabil* 2012;93:300–306.
- Hides JA, Stanton WR, Gilmore C, Bohlscheid E. Multifidus size and symmetry among chronic LBP and healthy asymptomatic subjects. *Man Ther* 2008;13:43–49.
- Macdonald DA, Moseley GL, Hodges PW. Why do some patients keep hurting their back? Evidence of ongoing back muscle dysfunction during remission from recurrent back pain. *Pain* 2009;142:183–188.
- Barker KL, Shamley DR, Jackson D. Changes in the cross-sectional area of multifidus and psoas in patients with unilateral back pain: the relationship to pain and disability. *Spine (Phila Pa 1976)* 2004;29:E515–E519.
- Crossman K, Mahon M, Watson PJ, Oldham JA, Cooper RG. Chronic low back pain-associated paraspinal muscle dysfunction is not the result of a constitutionally determined 'adverse' fiber-type composition. *Spine (Phila Pa 1976)* 2004;29: 628–634.
- Hides JA, Stanton W, Dilani Mendis M, Sexton M. The relationship of transversus abdominis and lumbar multifidus clinical muscle tests in patients with chronic low back pain. *Man Ther* 2011;10–14: 573–577. doi:10.1016/j.math.2011.05.007
- Danneels LA, Vanderstraeten GG, Cambier DC, Witvrouw EE, De Cuyper HJ. CT imaging of trunk muscles in chronic low back pain patients and healthy control subjects. *Eur Spine J* 2000;9:266–272.
- Yanik B, Keyik B, Conkbayir I. Fatty degeneration of multifidus muscle in patients with chronic low back pain and in asymptomatic volunteers: quantification with chemical shift magnetic resonance imaging. *Skeletal Radiol* 2013;42:771–778.
- Théron J, Guimaraens L, Casasco A, Coellar H, Sola T. Lumbosacral liposuction. A new tool for the treatment of low back pain. *Interv Neuroradiol* 2007;13:153–160.
- Hodges PW, James G, Blomster L et al. Multifidus muscle changes after back injury are characterized by structural remodeling of muscle, adipose and connective tissue, but not muscle atrophy. *Spine (Phila Pa 1976)* 2015;40:1057–1071.
- Kjaer P, Bendix T, Sorensen JS, Korsholm L, Leboeuf-Yde C. Are MRI-defined fat infiltrations in the multifidus muscles associated with low back pain? *BMC Med* 2007;5:2.
- Goubert D, Van Oosterwijck J, Meeus M, Danneels L. Structural changes of lumbar muscles in non-specific low back pain. *Pain Physician* 2016;19:E985–E1000.
- Pengel LHM, Herbert RD, Maher CG, Refshauge KM. Acute low back pain: systematic review of its prognosis. *BMJ* 2003;327:323.
- Itz CJ, Geurts JW, van Kleef M, Nelemans P. Clinical course of non-specific low back pain: a systematic review of prospective cohort studies set in primary care. *Eur J Pain* 2013;17:5–15.
- Hides JA, Richardson CA, Jull GA. Multifidus muscle recovery is not automatic after resolution of acute, first-episode low back pain. *Spine (Phila Pa 1976)* 1996;21: 2763–2769.
- Hides JA, Jull GA, Richardson CA. Long-term effects of specific stabilizing exercises for first-episode low back pain. *Spine (Phila Pa 1976)* 2001;26:E243–E248.
- Rice DA, McNair PJ. Quadriceps arthrogenic muscle inhibition: neural mechanisms and treatment perspectives. *Semin Arthritis Rheum* 2009;40:250–266. doi:10.1016/j.semarthrit.2009.10.001
- Rice DA, McNair PJ. Quadriceps arthrogenic muscle inhibition: neural mechanisms and treatment perspectives. *Semin Arthritis Rheum* 2010;40:250–266.
- Palmieri RM, Ingersoll CD, Hoffman MA et al. Arthrogenic muscle response to a simulated ankle joint effusion. *Br J Sports Med* 2004;38:26–30.

46. Tsao H, Danneels LA, Hodges PW. ISSLS prize winner: smudging the motor brain in young adults with recurrent low back pain. *Spine (Phila Pa 1976)* 2011;36:1721–1727.
47. Fritz JM, Koppenhaver SL, Kawchuk GN, Teyhen DS, Hebert JJ, Childs JD. Preliminary investigation of the mechanisms underlying the effects of manipulation: exploration of a multivariate model including spinal stiffness, multifidus recruitment, and clinical findings. *Spine (Phila Pa 1976)* 2011;36:1772–1781.
48. Young A. Current issues in arthrogenous inhibition. *Ann Rheum Dis* 1993;52:829–834.
49. Stevens VK, Coorevits PL, Bouche KG et al. The influence of specific training on trunk muscle recruitment patterns in healthy subjects during stabilization exercises. *Man Ther* 2006;12:271–279.
50. D'Hooge R, Hodges P, Tsao H, Hall L, Macdonald D, Danneels L. Altered trunk muscle coordination during rapid trunk flexion in patients in remission of recurrent low back pain. *J Electromyogr Kinesiol* 2013;23:173–181.
51. Kiesel KB, Butler RJ, Duckworth A et al. Experimentally induced pain alters the EMG activity of the lumbar multifidus in asymptomatic subjects. *Man Ther* 2012;17:236–240. doi:10.1016/j.math.2012.01.008
52. Wallwork TL, Stanton WR, Freke M, Hides JA. The effect of chronic low back pain on size and contraction of the lumbar multifidus muscle. *Man Ther* 2009;14:496–500.
53. Chan S-T, Fung P-K, Ng N-Y et al. Dynamic changes of elasticity, cross-sectional area, and fat infiltration of multifidus at different postures in men with chronic low back pain. *Spine J* 2012;12:381–388.
54. Teyhen D, Koppenhaver S. Rehabilitative ultrasound imaging. *J Physiother* 2011;57:196.
55. Annaswamy TM, Bierner SM, Doppalapudi H. Does lumbar dorsal ramus syndrome have an objective clinical basis? *PM R* 2013;5:996–1006.
56. Kiesel KB, Uhl TL, Underwood FB, Rodd DW, Nitz AJ. Measurement of lumbar multifidus muscle contraction with rehabilitative ultrasound imaging. *Man Ther* 2007;12:161–166.
57. Lee S-W, Chan C. K-M, Lam T-S et al. Relationship between low back pain and lumbar multifidus size at different postures. *Spine (Phila Pa 1976)* 2006;31:2258–2262.
58. Colloca CJ, Keller TS, Moore RJ, Gunzburg R, Harrison DE. Effects of disc degeneration on neurophysiological responses during dorsoventral mechanical excitation of the ovine lumbar spine. *J Electromyogr Kinesiol* 2007;18:829–837.
59. Hodges P, Galea M, Holm S, Kaigle Holm A. *Response of the Deep Paraspinal Muscles to Cortical but Not Transmastoid Stimulation Is Increased at a Single Lumbar Level Following Intervertebral Disc Lesion*. Paper presented at Progress in Motor Control VI, Mendes Convention Center, Santos, São Paulo, Brazil 2007. <http://demotu.org/pmcvi/viewabstract.php?id=228>.
60. Hodges PW, Holm AK, Hansson T, Holm S. Rapid atrophy of the lumbar multifidus follows experimental disc or nerve root injury. *Spine (Phila Pa 1976)* 2006;31:2926–2933.
61. Zhou B-H, Williams M, Solomonow M, Baratta RV, Harris M. Multifidus spasms elicited by prolonged lumbar flexion. *Spine (Phila Pa 1976)* 2000;25:2916–2924.
62. Brown SHM, Gregory DE, Carr JA et al. Adaptations to the multifidus muscle in response to experimentally induced intervertebral disc degeneration. *Spine (Phila Pa 1976)* 2011; 36:1728–1736. doi:10.1097/BRS.0b013e318212b44b
63. Panjabi MM. A hypothesis of chronic back pain: ligament subfailure injuries lead to muscle control dysfunction. *Eur Spine J* 2006;15:668–676.
64. Hodges PW, Moseley GL. Pain and motor control of the lumbopelvic region: effect and possible mechanisms. *J Electromyogr Kinesiol* 2003;13:361–370.
65. Brumagne S, Cordo P, Lysens R, Verschueren S, Swinnen S. The role of paraspinal muscle spindles in lumbosacral position sense in individuals with and without low back pain. *Spine (Phila Pa 1976)* 2000;25:989–994.
66. Dickx N, Cagnie B, Achten E, Vandemaële P, Parlevliet T, Danneels L. Changes in lumbar muscle activity because of induced muscle pain evaluated by muscle functional magnetic resonance imaging. *Spine (Phila Pa 1976)* 2008;33:E983–E989.
67. Kiesel KB, Underwood FB, Mattacola CG, Nitz AJ, Malone TR. A comparison of select trunk muscle thickness changes between subjects with low back pain classified in the treatment-based classification system and asymptomatic controls. *J Orthop Sports Phys Ther* 2007;37:596–607. doi:10.2519/jospt.2007.2574
68. Kiesel KB, Uhl T, Underwood FB, Nitz AJ. Rehabilitative ultrasound measurement of select trunk muscle activation during induced pain. *Man Ther* 2008;13:132–138.
69. Danneels L, Coorevits P, Cools A et al. Differences in electromyographic activity in the multifidus muscle and the iliocostalis lumborum between healthy subjects and patients with sub-acute and chronic low back pain. *Eur Spine J* 2002; 11:13–19.
70. D'Hooge R, Cagnie B, Crombez G, Vanderstraeten G, Achten E, Danneels L. Lumbar muscle dysfunction during remission of unilateral recurrent nonspecific low-back pain: evaluation with muscle functional MRI. *Clin J Pain* 2013;29:187–194.
71. Dubois J-D, Piché M, Cantin V, Descarreaux M. Effect of experimental low back pain on neuromuscular control of the trunk in healthy volunteers and patients with chronic low back pain. *J Electromyogr Kinesiol* 2011;21:774–781. doi:10.1016/j.jelekin.2011.05.004
72. Wand BM, Parkitny L, O'Connell NE et al. Cortical changes in chronic low back pain: current state of the art and implications for clinical practice. *Man Ther* 2011; 16:15–20.
73. Massé-Alarie H, Beaulieu L-D, Preuss R, Schneider C. Corticomotor control of lumbar multifidus muscles is impaired in chronic low back pain: concurrent evidence from ultrasound imaging and double-pulse transcranial magnetic stimulation. *Exp Brain Res* 2015; 234:1033–1045. doi:10.1007/s00221-015-4528-x
74. Tsao H, Galea MP, Hodges PW. Reorganization of the motor cortex is associated with postural control deficits in recurrent low back pain. *Brain* 2008;131:2161–2171.
75. Tsao H, Danneels L, Hodges PW. Individual fascicles of the paraspinal muscles are activated by discrete cortical networks in humans. *Clin Neurophysiol* 2011;122:1580–1587.
76. Tsao H, Galea MP, Hodges PW. Driving plasticity in the motor cortex in recurrent low back pain. *Eur J Pain* 2010;14:832–839.
77. Schabrun SM, Elgueta-Cancino EL, Hodges PW. Smudging of the Motor Cortex is related to the Severity of Low Back Pain. *Spine (Phila Pa 1976)* 2015;1:38. doi:10.1097/BRS.0000000000000938
78. Seminowicz DA, Wideman TH, Naso L et al. Effective treatment of chronic low back pain in humans reverses abnormal brain anatomy and function. *J Neurosci* 2011;31:7540–7550.
79. Kalichman L, Carmeli E, Been E. The association between imaging parameters of the paraspinal muscles, spinal degeneration, and low back pain. *Biomed Res Int* 2017;2017:1.
80. Hides JA, Belavý DL, Stanton W et al. Magnetic resonance imaging assessment of trunk muscles during prolonged bed rest. *Spine (Phila Pa 1976)* 2007;32:1687–1692.
81. Hides JA, Lambrecht G, Richardson CA et al. The effects of rehabilitation on the muscles of the trunk following prolonged bed rest. *Eur Spine J* 2011;20:808–818.
82. Le Cara EC, Marcus RL, Dempsey AR, Hoffman MD, Hebert JJ. Morphology versus function: the relationship between lumbar multifidus intramuscular adipose tissue and muscle function among patients with low back pain. *Arch Phys Med Rehabil* 2014;95:1846–1852.
83. Hildebrandt M, Fankhauser G, Meichtry A, Luomajoki H. Correlation between lumbar dysfunction and fat infiltration in lumbar multifidus muscles in patients with low back pain. *BMC Musculoskelet Disord* 2017;18:12.
84. Fortin M, Gibbons LE, Videman T, Battié MC. Do variations in paraspinal muscle morphology and composition predict low back pain in men? *Scand J Med Sci Sports* 2014;25:880–887. doi:10.1111/sms.12301
85. Zielinski KA, Henry SM, Ouellette-Morton RH, DeSarno MJ. Lumbar multifidus muscle thickness does not predict patients with low back pain who improve with trunk stabilization exercises. *Arch Phys Med Rehabil* 2013;94:1132–1138.
86. Ghamkhar L, Emami M, Mohseni-Bandpei MA, Behtash H. Application of rehabilitative ultrasound in the assessment of low back pain: a literature review. *J Bodyw Mov Ther* 2011;15:465–477.
87. Wong AYL, Parent EC, Funabashi M, Stanton TR, Kawchuk GN. Do various baseline characteristics of transversus abdominis and lumbar multifidus predict clinical outcomes in nonspecific low back pain? A systematic review. *Pain* 2013;154:2589–2602.
88. Stokes IAF, Henry SM, Single RM. Surface EMG electrodes do not accurately record from lumbar multifidus muscles. *Clin Biomech (Bristol, Avon)* 2003;18:9–13.
89. Gondhalekar GA, Kumar SP, Eapen C, Mahale A. Reliability and validity of standing back extension test for detecting motor control impairment in subjects with low back pain. *J Clin Diagn Res* 2016;10:KC07–KC11.
90. Hicks GE, Fritz JM, Delitto A, McGill SM. Preliminary development of a clinical prediction rule for determining which patients with low back pain will respond to a stabilization exercise program. *Arch Phys Med Rehabil* 2005;86:1753–1762.
91. Hebert JJ, Koppenhaver SL, Teyhen DS, Walker BF, Fritz JM. The evaluation of lumbar multifidus muscle function via palpation: reliability and validity of a new clinical test. *Spine J* 2015;15:1196–1202.
92. Denteneer L, Stassijns G, De Hertogh W, Truijzen S, Van Daele U. Interrater reliability of clinical tests associated with functional lumbar segmental instability and motor control impairment in patients with low back pain: a systematic review. *Arch Phys Med Rehabil* 2017;98:151–164.e6.
93. Hicks GE, Fritz JM, Delitto A, Mishock J. Interrater reliability of clinical examination measures for identification of lumbar segmental instability. *Arch Phys Med Rehabil* 2003;84:1858–1864.
94. Hebert JJ, Koppenhaver SL, Magel JS, Fritz JM. The relationship of transversus abdominis and lumbar multifidus activation and prognostic factors for clinical success with a stabilization exercise program: a cross-sectional study. *Arch Phys Med Rehabil* 2010;91:78–85.
95. Rabin A, Shashua A, Pizem K, Dickstein R, Dar G. A clinical prediction rule to identify patients with low back pain who are likely to experience short-term success following lumbar stabilization exercises: a randomized controlled validation study. *J Orthop Sports Phys Ther* 2014;44:6–B13.
96. Barr KP, Griggs M, Cadby T. Lumbar stabilization: core concepts and current literature, Part 1. *Am J Phys Med Rehabil* 2005;84:473–480.
97. Lederman E. The myth of core stability. *J Bodyw Mov Ther* 2010;14:84–98.
98. Standaert CJ, Herring SA. Expert opinion and controversies in musculoskeletal and sports medicine: core stabilization as a treatment for low back pain. *Arch Phys Med Rehabil* 2007;88:1734–1736.
99. Kumar S, Sharma VP, Aggarwal A, Shukla R, Dev R. Effect of dynamic muscular stabilization technique on low back pain of different durations. *J Back Musculoskelet Rehabil* 2012;25:73–79.
100. Hides JA, Stanton WR, Mendis MD, Gildea J, Sexton MJ. Effect of motor control training on muscle size and football games missed from injury. *Med Sci Sports Exerc* 2011;44:1141–1149. doi:10.1249/MSS.0b013e318244a321
101. Macedo LG, Maher CG, Latimer J, McAuley JH. Motor control exercise for persistent, nonspecific low back pain: a systematic review. *Phys Ther* 2009;89:9–25.
102. Saragiotto BT, Maher CG, Yamato TP et al. Motor control exercise for chronic nonspecific low-back pain. *Cochrane Database Syst Rev* 2016;1:CD012004.

103. Hauggaard A, Persson AL. Specific spinal stabilisation exercises in patients with low back pain – a systematic review. *Phys Ther Rev* 2007;12:233–248.
104. May S, Johnson R. Stabilisation exercises for low back pain: a systematic review. *Physiotherapy* 2008;94:179–189.
105. Byström MG, Rasmussen-Barr E, Johannes W, Grooten A, Grooten WJA. Motor control exercises reduces pain and disability in chronic and recurrent low back pain: a meta-analysis. *Spine (Phila Pa 1976)* 2013;38:E350–E358.
106. Standaert CJ, Weinstein SM, Rumpeltes J. Evidence-informed management of chronic low back pain with lumbar stabilization exercises. *Spine J* 2008;8:114–120.
107. Smith BE, Littlewood C, May S. An update of stabilisation exercises for low back pain: a systematic review with meta-analysis. *BMC Musculoskelet Disord* 2014;15:1–21.
108. Wang X-Q, Zheng JJ, Yu ZW et al. A meta-analysis of core stability exercise versus general exercise for chronic low back pain. *PLoS One* 2012;7:e52082.
109. Willemink MJ, van Es HW, Helmhout PH et al. The effects of dynamic isolated lumbar extensor training on lumbar multifidus functional cross-sectional area and functional status of patients with chronic nonspecific low back pain. *Spine (Phila Pa 1976)* 2012;37:E1651–E1658.
110. Akuthota V, Nadler S. Core strengthening. *Arch Phys Med Rehabil* 2004;85:86–92.
111. Van K, Hides JA, Richardson CA. The use of real-time ultrasound imaging for biofeedback of lumbar multifidus muscle contraction in healthy subjects. *J Orthop Sports Phys Ther* 2006;36:920–925.
112. Goldby LJ, Moore AP, Doust J, Trew ME. A randomized controlled trial investigating the efficiency of musculoskeletal physiotherapy on chronic low back disorder. *Spine (Phila Pa 1976)* 2006;31:1083–1093.
113. França FR, Burke TN, Caffaro RR, Ramos LA, Marques AP. Effects of muscular stretching and segmental stabilization on functional disability and pain in patients with chronic low back pain: a randomized, controlled trial. *J Manipulative Physiol Ther* 2012;35:279–285.
114. Koppenhaver SL, Fritz JM, Hebert JJ et al. Association between history and physical examination factors and change in lumbar multifidus muscle thickness after spinal manipulation in patients with low back pain. *J Electromyogr Kinesiol* 2012;22:724–731.
115. Koppenhaver SL, Fritz JM, Hebert JJ et al. Association between changes in abdominal and lumbar multifidus muscle thickness and clinical improvement after spinal manipulation. *J Orthop Sports Phys Ther* 2011;41:389–399. doi:10.2519/jospt.2011.3632
116. Hides JA, Stanton WR, McMahon S, Sims K, Richardson CA. Effect of stabilization training on multifidus muscle cross-sectional area among young elite cricketers with low back pain. *J Orthop Sports Phys Ther* 2008;38:101–108.
117. Harringe ML, Nordgren JS, Arvidsson I, Werner S. Low back pain in young female gymnasts and the effect of specific segmental muscle control exercises of the lumbar spine: a prospective controlled intervention study. *Knee Surg Sports Traumatol Arthrosc* 2007;15:1264–1271.
118. O'Sullivan PB, Phytz GD, Twomey LT, Alon G. Evaluation of specific stabilizing exercise in the treatment of chronic low back pain with radiologic diagnosis of spondylolysis or spondylolisthesis. *Spine (Phila Pa 1976)* 1997;22:2959–2967.
119. Imoto AM, Peccin S, Almeida GJM, Saconato H, Atallah ÁN. Effectiveness of electrical stimulation on rehabilitation after ligament and meniscal injuries: a systematic review. *Sao Paulo Med J* 2011;129:414–423.
120. Stevens JE, Mizner RL, Snyder-Mackler L. Quadriceps strength and volitional activation before and after total knee arthroplasty for osteoarthritis. *J Orthop Res* 2003;21:775–779.
121. Stevens-Lapsley JE, Balter JE, Wolfe P, Eckhoff DG, Kohrt WM. Early neuromuscular electrical stimulation to improve quadriceps muscle strength after total knee arthroplasty: a randomized controlled trial. *Phys Ther* 2012;92:210–226.
122. Avramidis K, Strike PW, Taylor PN, Swain ID. Effectiveness of electric stimulation of the vastus medialis muscle in the rehabilitation of patients after total knee arthroplasty. *Arch Phys Med Rehabil* 2003;84:1850–1853.
123. Stevens JE, Mizner RL, Snyder-Mackler L. Neuromuscular electrical stimulation for quadriceps muscle strengthening after bilateral total knee arthroplasty: a case series. *J Orthop Sports Phys Ther* 2004;34:21–29.
124. Kim K-M, Croy T, Hertel J, Saliba S. Effects of neuromuscular electrical stimulation after anterior cruciate ligament reconstruction on quadriceps strength, function, and patient-oriented outcomes: a systematic review. *J Orthop Sports Phys Ther* 2010;40:383–391.
125. Walls RJ, McHugh G, Moyna NM, O'Byrne J. Efficacy and compliance of a quadriceps femoris neuromuscular stimulation program in subjects with severe knee osteoarthritis. *Orthopaedic Proc* 2009;91-B(Suppl III):457.
126. Gondin J, Guette M, Martin A. Neural and muscular changes after 4 and 8 weeks of electromyostimulation training. *Comput Methods Biomech Biomed Eng* 2005;8:119–120.
127. Gondin J, Duclay J, Martin A. Neural drive preservation after detraining following neuromuscular electrical stimulation training. *Neurosci Lett* 2006;409:210–214.
128. Carnaby-Mann GD, Crary MA. Examining the evidence on neuromuscular electrical stimulation for swallowing: a meta-analysis. *Arch Otolaryngol Head Neck Surg* 2007;133:564–571.
129. Baek SO, Ahn SH, Jones R et al. Activations of deep lumbar stabilizing muscles by transcutaneous neuromuscular electrical stimulation of lumbar paraspinal regions. *Ann Rehabil Med* 2014;38:506.
130. Bilgin S, Temucin CM, Nurlu G et al. Effects of exercise and electrical stimulation on lumbar stabilization in asymptomatic subjects: a comparative study. *J Back Musculoskelet Rehabil* 2013;26:261–266.
131. Deckers K, De Smedt K, van Buyten J-P et al. Chronic low back pain: restoration of dynamic stability. *Neuromodulation* 2015;18:478–486.
132. Deckers K, De Smedt K, Mitchell B, et al. New therapy for refractory chronic mechanical low back pain – restorative neurostimulation to activate the lumbar multifidus: one year results of a prospective multicenter clinical trial. *Neuromodulation* 2017. In press. doi:10.1111/ner/12741
133. Brosseau L, Milne S, Robinson V et al. Efficacy of the transcutaneous electrical nerve stimulation for the treatment of chronic low back pain: a meta-analysis. *Spine (Phila Pa 1976)* 2002;27:596–603.